

ROLE OF OZONE TREATMENT IN DISC LESIONS IN DIABETIC PATIENTS

Prof. Umair Rashid Chaudhry
Neuroradiology Department
Lahore General Hospital,
Lahore - Pakistan



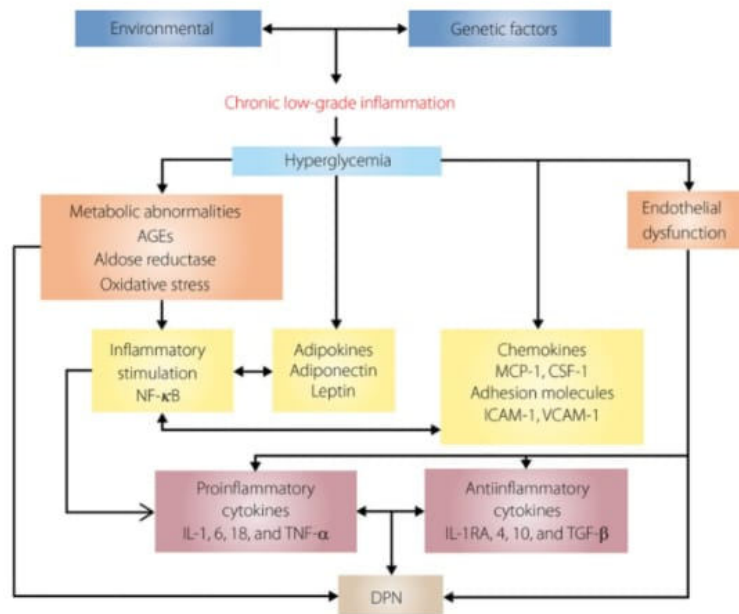
1

- **Importance of cytokines
enzymes in disc lesions and
Diabetic patients**



2

Figure 1



3

Diabetic Neuropathy

- Radiculopathy
- Peripheral Neuropathy

4

DISC LESIONS IN DIABETICS



- L 4-5 level more common sites
- 50 years or above
- Sex
 - More dominate in males
- Sessions
 - 4 to 6

5

DIFFERENT TECHNIQUES



- Chemodiscolysis with chymopapain
- Percutaneous laser disc decompression (PLDD)
- Intradiscal electrothermal therapy (IDET)
- Percutaneous coablation nucleoplasty
- **Chemodiscolysis with O₂-O₃ mixture**
- Others, Jellified ethyl alcohol (discogel) etc.

6

Original Article

American Journal of Neuroradiology May 2003

Minimally Invasive Oxygen-Ozone Therapy for Lumbar Disk Herniation

Cosma F. Andreula(b), Luigi Simonetti(a), Fabio de Santis(a),
Raffaele Agati(a), Renata Ricci(a) and Marco Leonardi(a)

ABSTRACT

BACKGROUND AND PURPOSE: Oxygen-ozone therapy is a minimally invasive treatment for lumbar disk herniation that exploits the biochemical properties of a gas mixture of oxygen and ozone. We assessed the therapeutic outcome of oxygen-ozone therapy and compared the outcome of administering medical ozone alone with the outcome of medical ozone followed by injection of a corticosteroid and an anesthetic at the same session.

METHODS: Six hundred patients were treated with a single session of oxygen-ozone therapy. All presented with clinical signs of lumbar disk nerve root compression, with CT and/or MR evidence of contained disk herniation. Three hundred patients (group A) received an intradiscal (4 mL) and periganglionic (8 mL) injection of an oxygen-ozone mixture at an ozone concentration of 27 µg/mL. The other 300 patients (group B) received, in addition, a periganglionic injection of corticosteroid and anesthetic. Therapeutic outcome was assessed 6 months after treatment by using a modified MacNab method. Results were evaluated by two observers blinded to patient distribution within the two groups.

RESULTS: A satisfactory therapeutic outcome was obtained in both groups. In group A, treatment was a success (excellent or good outcome) in 70.3% and deemed a failure (poor outcome or recourse to surgery) in the remaining 29.7%. In group B, treatment was a success in 78.3% and deemed a failure in the remaining 21.7%. The difference in outcome between the two groups was statistically significant ($P < .05$).

CONCLUSION: Combined intradiscal and periganglionic injection of medical ozone and periganglionic injection of steroids has a cumulative effect that enhances the overall outcome of treatment for pain caused by disk herniation. Oxygen-ozone therapy is a useful treatment for lumbar disk herniation that has failed to respond to conservative management.

(a) Department of Neuroradiology, Ospedale Bellaria, Bologna, Italy
(b) Ospedale Policlinico, Bari, Italy
Address reprint requests to Marco Leonardi, MD, Servizio di Neuroradiologia, Ospedale Bellaria, Via Altura 3, 40139 Bologna, Italy


American Journal of Neuroradiology May 2003, 24 (5) 996-1000

7

MOA


- **N.P.**
- **Fibrous Annulus**

8



- **Angio Fluoro guided**
- CT guided

9



O₂ O₃ therapy is a new percutaneous technique with proved clinical efficacy and clinical application in selected patients with cervical & low back pain and sciatica.

10

OZONUCLEOLYSIS



- Intradiscal
- Intradiscal with periganglionic
- Paravertabral

11

INCLUSION CRITERIA



- Sciatica / Brachalgeia not responding to conservative treatment
- MRI / Myelo-CT/ Myelography ++

12

EXCLUSION CRITERIA



- **Pregnancy**
- **Motor Loss**
- **A full blown cauda quina sym.**
- **Calcified Disc**
- **G6PD deficiency**

13

EFFECTS



- **Indirect**
 - **Analgesic**
 - **Anti inflammatory**
 - **Oxygenation**
- **Direct**
 - **Shrinkage**

14



AGE:
40 to 75 years

15



**LESIONS TREATED
DIABETIC CASES**

- **Single Disc prolapse**
- **Multiple Disc prolapse**
- **Spinal Stenosis with Discs**
- **Spondylolisthesis with Disc**
- **Failed back syndrome**
- **Dessicated disc with symptoms**

16

SESSIONS:

SINGLE

MULTIPLE

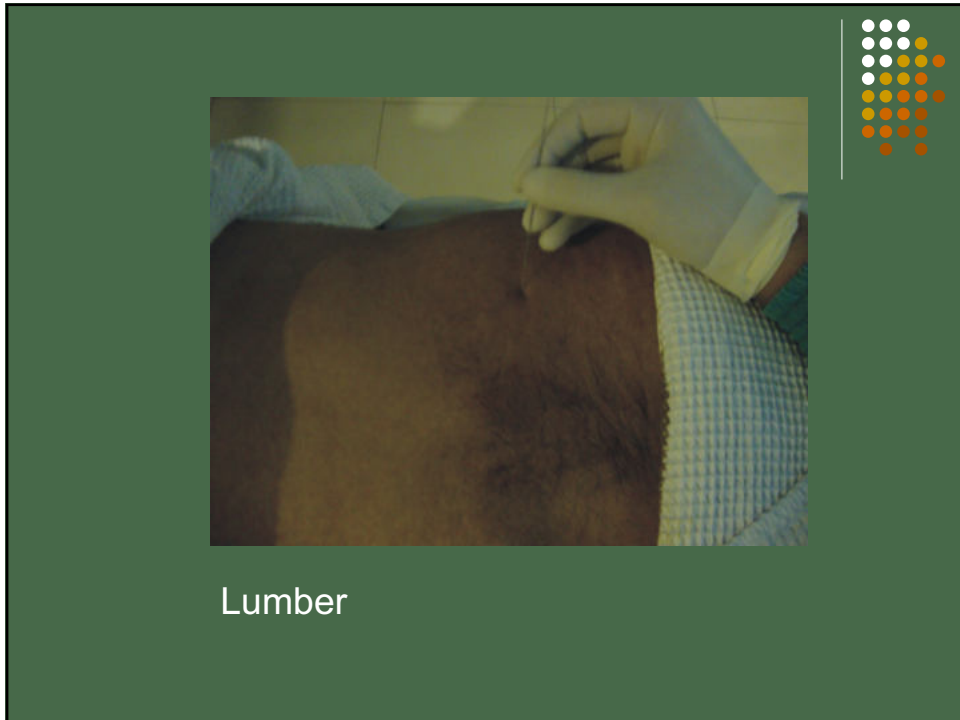

17

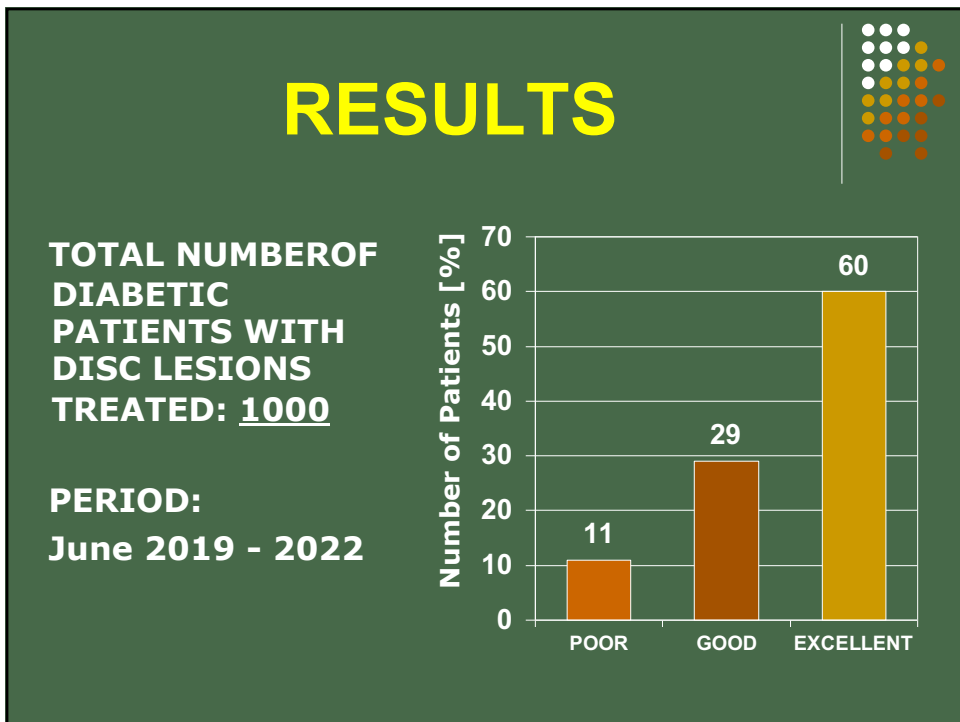


15 to 20 minutes

18



19



20

COMPLICATIONS



- **No early or late neurological complications have been reported following O₂ O₃ injection.**

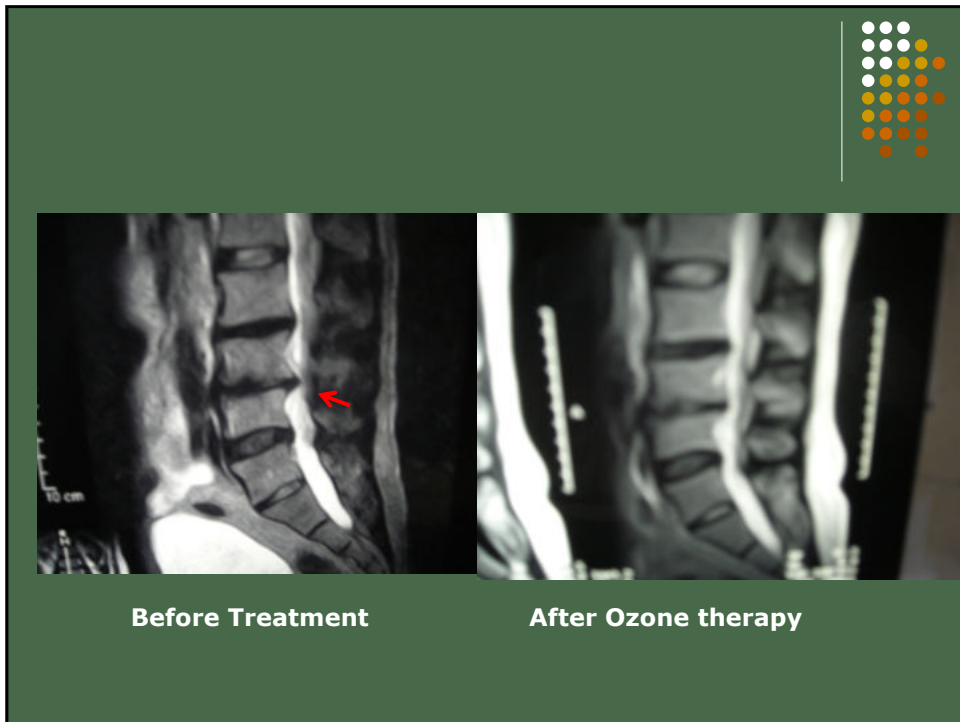21

CONCLUSION

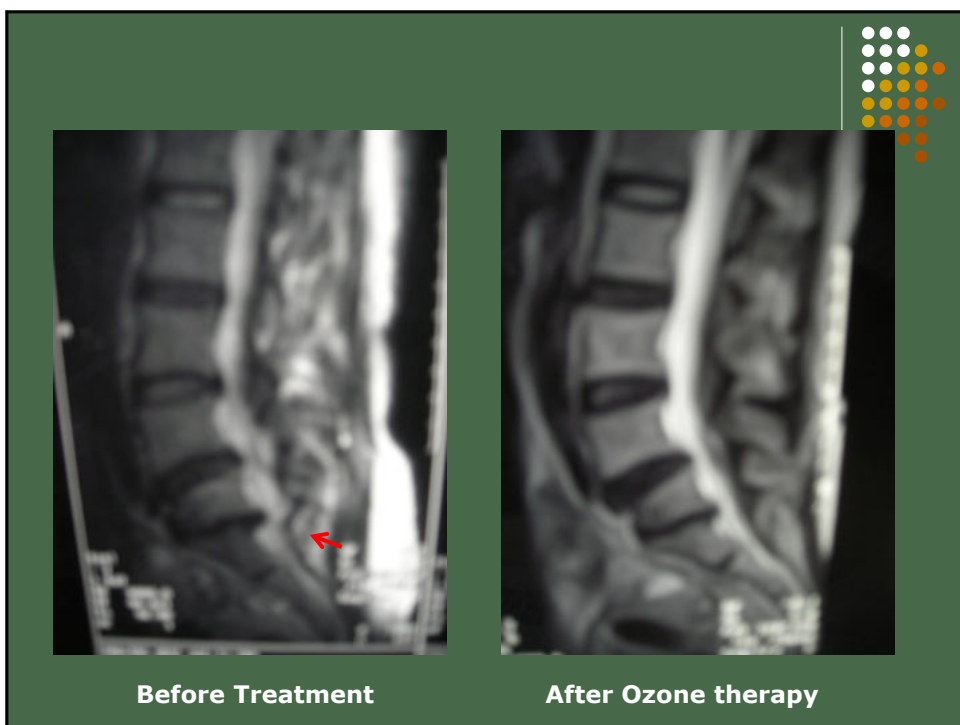

- Good results
- Minimal invasive
- Lack of complications
- Short hospital stay
- Low Cost
- Injection can be repeated
- This procedure has the potential to become a treatment of choice for discogenic radiculopathy.

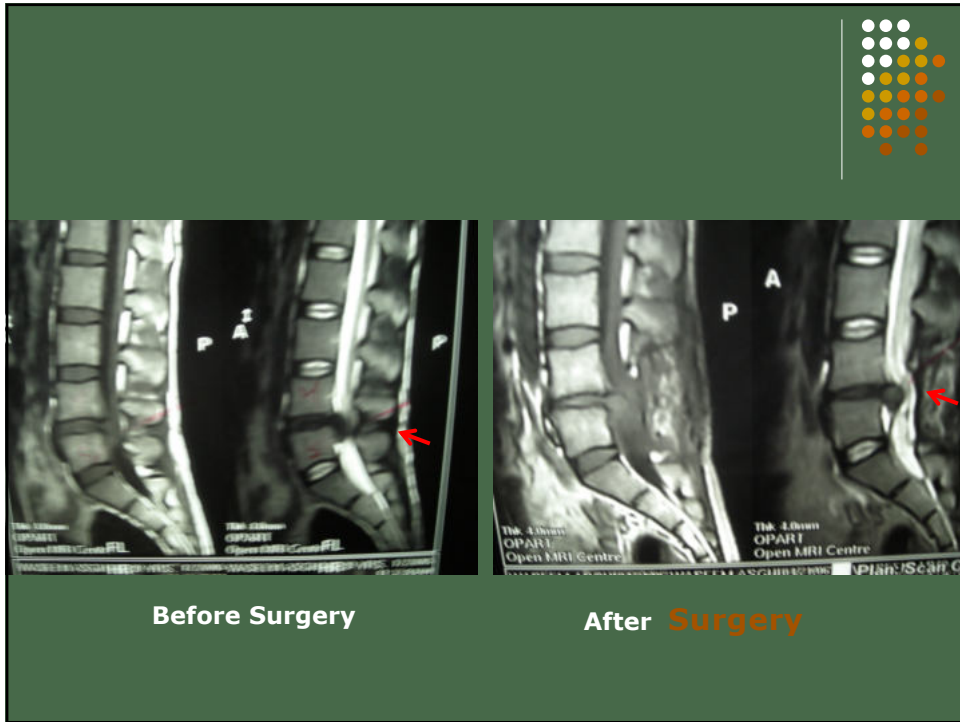
22



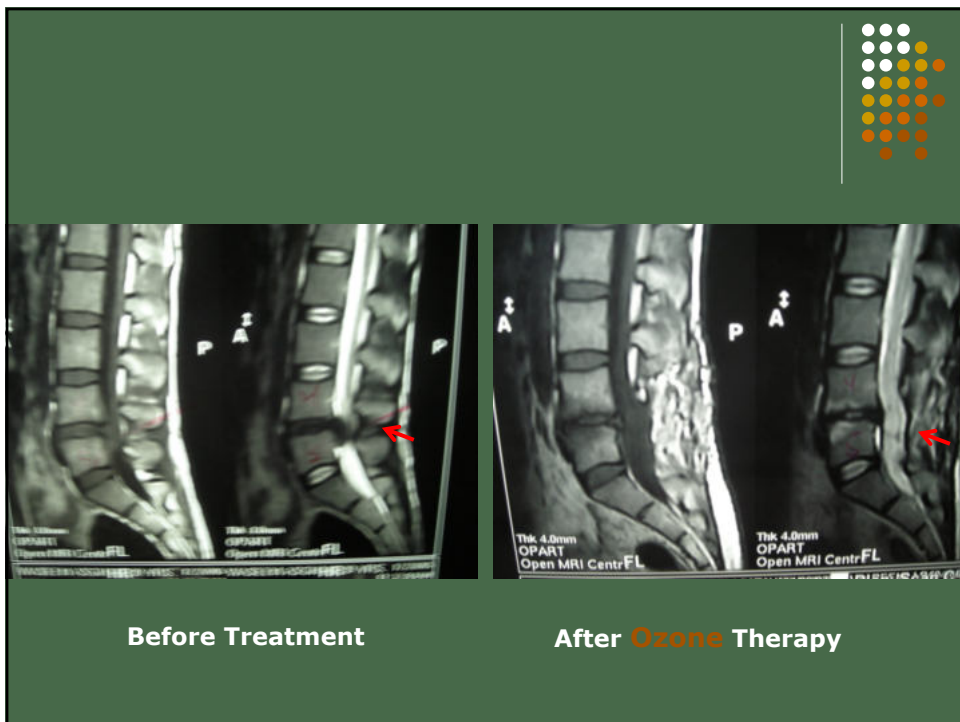
23



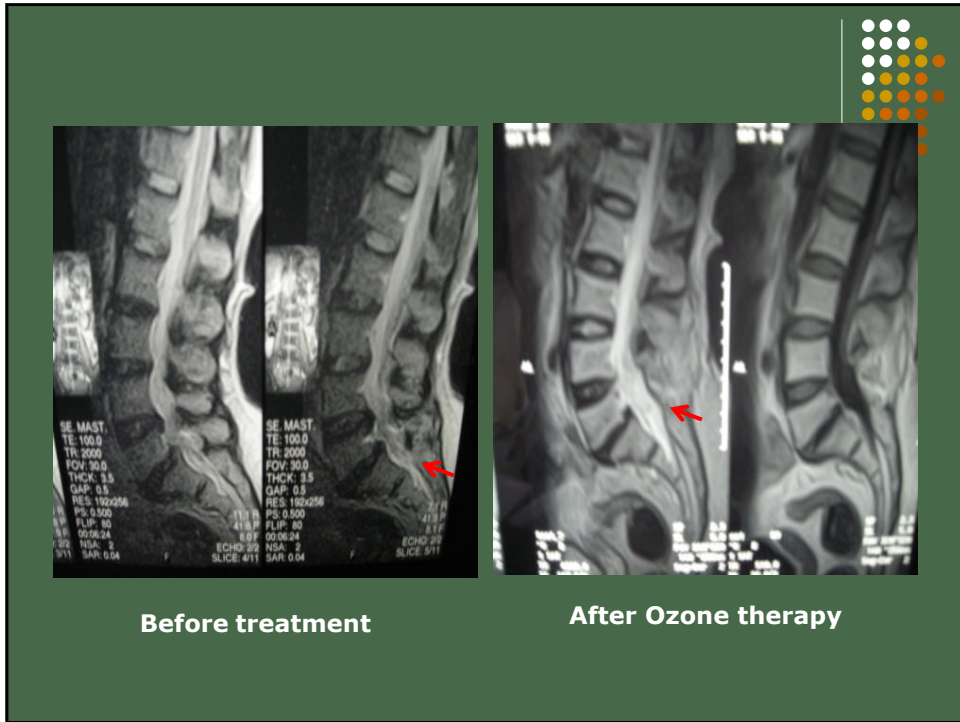
24



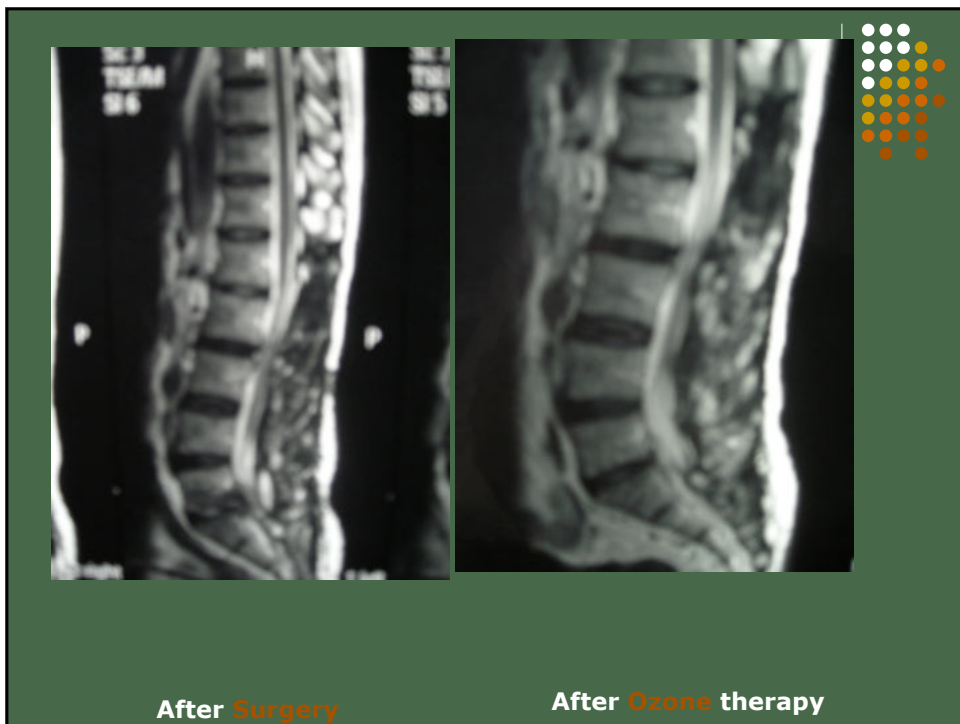
25



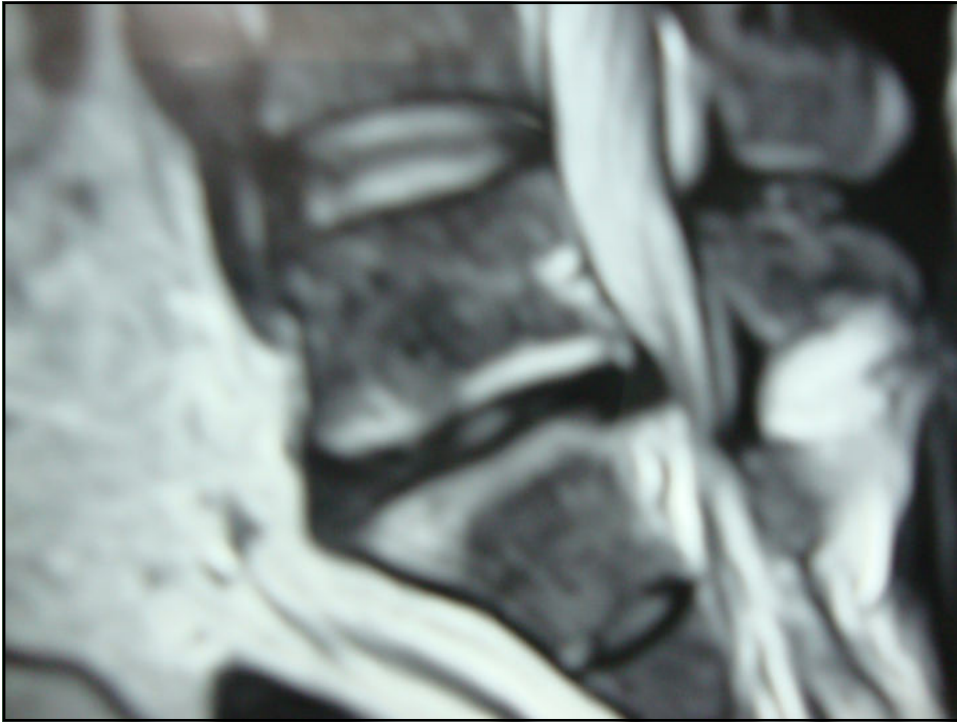
26



27



28



31